

## Acoustic Pulse Thrombolysis™ Treatment: Rapid Clearing of DVT in young patient

Dr Med. Nils Kucher, FESC, Swiss Cardiovascular Center, University of Bern, Switzerland

### Patient History

**16yo girl on oral contraceptives presented with inguinal pain for 7 days and significant swelling of the left leg for 24 hours.**

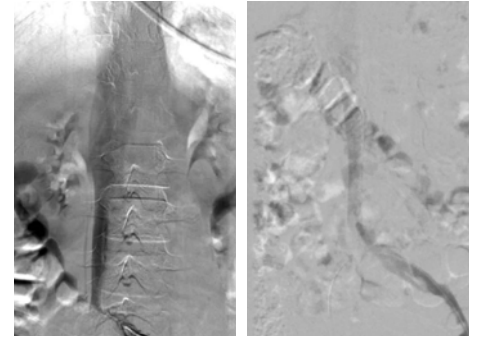
- Angiography confirmed the presence of occlusive thrombus from the distal superficial femoral vein (SFV) to the iliac vein and a non-obstructive thrombus in the distal inferior vena cava (IVC)
- Thrombus was also present in the external iliac and femoral veins

### Treatment

**Access was obtained through the popliteal vein**

- A 50 cm treatment length EkoSonic™ Endovascular device was placed with the treatment zone extending from the distal SFV to the distal IVC.
- Actilyse started at 2 mg/hour for 6 hours, then reduced to 1 mg/hour for 12 hours
- Total dose of Actilyse: 24 mg
- Total infusion time: 18 hours
- Unfractionated heparin (UFH) infusion initiated at 20,000 U/24 hour through popliteal sheath (dose titrated to maintain therapeutic aPTT)
- UHF discontinued at 48 hours; fondaparinux started at 7.5 mg OD as bridge to K antagonist

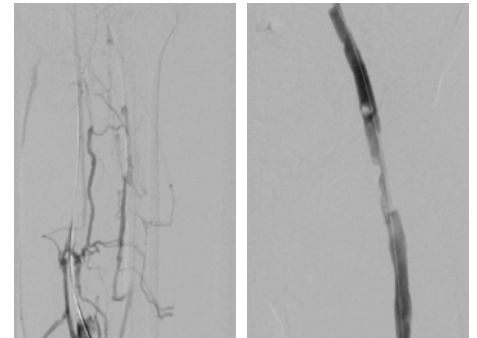
Iliac Vein & IVC



Pre

Post

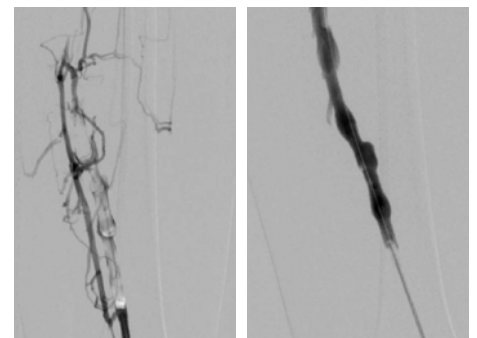
Proximal SFV



Pre

Post

Distal SFV



Pre

Post

## Acoustic Pulse Thrombolysis™ Treatment: Rapid Clearing of DVT in young patient

Dr Med. Nils Kucher, FESC, Swiss Cardiovascular Center, University of Bern, Switzerland

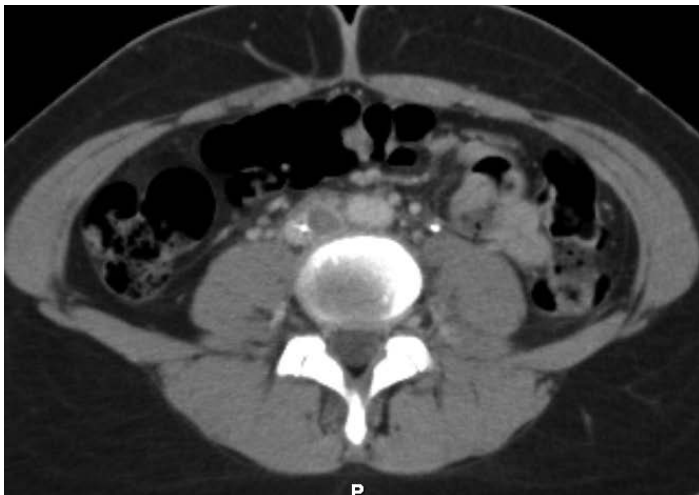
### Results

#### Angiography after 18 hour infusion demonstrated complete resolution of SFV and iliac thrombus

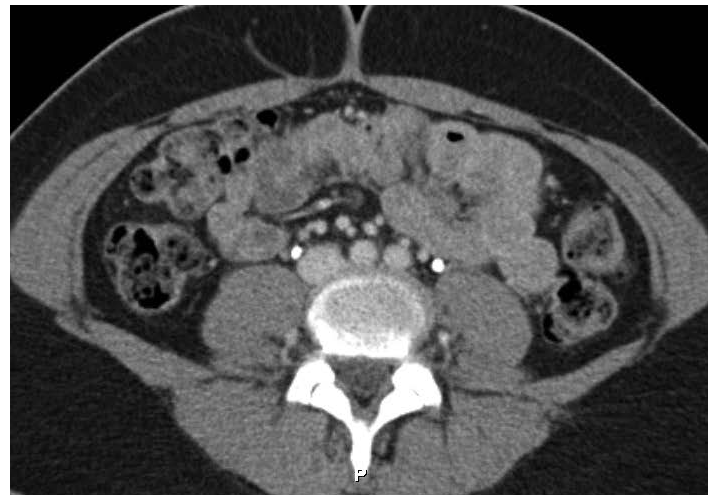
- Non-obstructive clot in the inferior vena cava was not affected by the procedure and there was residual clot in the external iliac and femoral veins.
- Patient experienced rapid recovery of leg swelling within 16 hours of EKOS™ treatment.
- Venous ultrasound at 6 weeks showed no residual thrombus in the deep venous system with normal valvular function without reflux. There were no clinical signs of chronic venous insufficiency at 6 weeks.
- Follow-up computed tomography showed complete lysis.

“Rapid resolution of thrombus with resultant brisk flow resolved this patient’s symptoms within 24 hours and will prevent post-thrombotic syndrome in this very young patient.”

– Nils Kucher, MD



CT during treatment showing EKOS™ device (solid arrow) and thrombus in IVC (open arrow)



6 week follow-up CT showing complete thrombus resolution in IVC (arrow)

Imagine where we can go.

**Indications for use:** The EkoSonic™ Endovascular System is intended for controlled and selective infusion of physician-specified fluids, including thrombolytics, into the peripheral vasculature. The EkoSonic™ Endovascular System is CE Marked for the treatment of pulmonary embolism with a  $\geq 50\%$  clot burden in one or both main pulmonary arteries or lobar pulmonary arteries, and evidence of right heart dysfunction based on right heart pressures (mean pulmonary artery pressure  $\geq 25$  mmHg) or echocardiographic evaluation. **Contraindications:** Not designed for peripheral vasculature dilation purposes. This system is contraindicated when, in the medical judgment of the physician, such a procedure may compromise that patient's condition. Such conditions include but are not limited to: • Tortuous vascular anatomy compromising safe introduction of endovascular equipment • Conditions associated with increased risk of bleeding. See device instructions for use for complete prescribing information [http://ekoscorp.com/international\\_enter.htm#Resources](http://ekoscorp.com/international_enter.htm#Resources)

EKOS, the EKOS logo, Acoustic Pulse Thrombolysis and EkoSonic are trademarks of EKOS Corporation, a BTG International group company. EKOS is a registered trademark in the US, EU and certain other territories. 'Imagine where we can go', BTG and the BTG roundel logo are trademarks of BTG International Ltd. BTG and the BTG roundel logo are registered trademarks in the US, EU and certain other territories. All rights reserved. © 2015 EKOS Corporation. GXUS-EKO-2015-0207



[btg-im.com](http://btg-im.com)